

A Morphological and Morphometric Study of Glenoid Fossa of Scapula and its Implication in Shoulder Arthroplasty

ARCHANA SINGH¹, ARUN SINGH², PREETI AGARWAL³, RAKESH GUPTA⁴

ABSTRACT

Introduction: Glenoid fossa of scapula articulates with the head of humerus and forms gleno-humeral joint (shoulder Joint). So, the knowledge of various shapes and size of glenoid fossa is useful to clinician for better understanding of various diseases associated with the joint and also helpful to orthopaedician to choose the right prosthesis for shoulder replacement surgeries.

Aim: To observe the shape and to measure the various diameters of glenoid fossa in adult dry human scapulae.

Materials and Methods: Total of 100 dry adult human scapulae of unknown sex and age were obtained from the museum of anatomy and forensic medicine and were included in present study. Out of total 100 scapulae, 56 were of right side and 44 were of left side. Various shapes of glenoid fossa were observed on the basis of presence or absence of notch.

Morphometric parameters such as Superio-Inferior Diameter (SI), Anterio-Posterior Diameter-1 (AP-1) and Anterio-Posterior Diameter-2 (AP-2) were measured by digital Vernier caliper. All the parameters were tabulated and analysed statistically.

Results: In the present study most common shape of glenoid fossa was Pear shape that is 44% (42.9% on right, 45.5% on left), followed by oval shape in 34% (35.7% on right, 31.8% on left side) and inverted comma shape in 22% scapulae (21.4% on right side, 22.7% on left side). The mean measured values in total scapulae were; SI diameter was 34.24±3.27 mm, AP-1 diameter was 23.93±2.67 mm, AP-2 diameter was 12.96±1.84 mm and glenoid cavity index was 70.12±7.13 mm.

Conclusion: Morphological and Morphometric analysis of glenoid fossa of scapula help clinicians and orthopaedicians in shoulder arthroplasty and its associated shoulder diseases.

Keywords: Glenoid cavity index, Gleno-humeral joint, Glenoid cavity, Humerus, Shoulder joint

INTRODUCTION

The scapulae or shoulder blade is paired bone of shoulder girdle. It is situated posterior-lateral over the chest wall and extends from second rib to seventh rib. It has three angles; medial, lateral and superior, three borders; medial, lateral and superior and two surfaces; anterior or costal and posterior or dorsal. Scapula possess three process; acromion, coracoid and spinous. Lateral angle of scapula is truncated and possess the cavity known as glenoid fossa. It is directed forward, laterally and slightly upward [1]. Various shapes of glenoid fossa like oval, pear and inverted comma were reported on the basis of presence or absence of notch at the anterior margin of glenoid fossa. Notch is absent in oval shape, indistinct in pear shape and distinct in inverted comma shape of glenoid cavity [2,3].

Glenoid fossa is related to supra-glenoid tubercle at the upper margin of fossa and an infra-glenoid tubercle at the lower margin at the superior end of lateral border of scapula. Supra-glenoid tubercle lies inside the joint capsule of shoulder joint whereas infra-glenoid tubercle outside the capsule. Glenoid fossa articulates with the head of humerus and forms the gleno-humeral joint. The articular surface of glenoid fossa is concave and much smaller than the articular surface of head of humerus which is reciprocally convex. Both the articular surfaces are covered with articular cartilage (hyaline cartilage). The concavity of glenoid fossa is deepened by the glenoid labrum, attached to the margin of fossa which is fibro-cartilaginous rim. In spite of this both the articulating surfaces are not well congruent in many joint movement positions so, the joint is loosely packed. It is probably closely packed in abduction and lateral rotation of the joint [1].

Rotator cuff diseases and tear are found to be associated with the degree of inclination of the glenoid fossa [4]. It is important to know the morphological and morphometric variation of glenoid fossa to understand and diagnose the dislocations of joint and diseases of rotator cuff [5].

The knowledge of variation in shape and morphometric dimensions of glenoid fossa may help the clinician or orthopaedician to deal with various medical and surgical problems associated with the shoulder joint like; osteoarthritis, joint instability and osseous Bankart's lesion. It may also help to choose the appropriate size of prosthesis in shoulder arthroplasty and reduces the morbidity associated with this.

In northern region of India, the studies are scarce [5]; hence the present study was conducted to observe the shape of glenoid fossa and to measure the various diameters of glenoid fossa in adult dry human scapula.

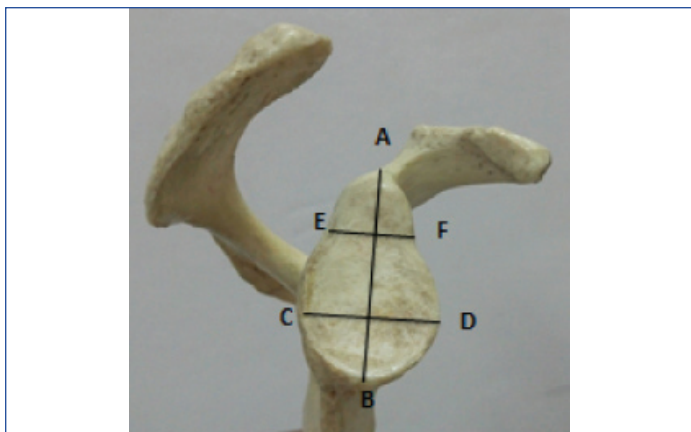
MATERIALS AND METHODS

This cross sectional study was done on total of 100 dry adult human scapulae obtained from the museum of Department of Anatomy and Forensic Medicine and Toxicology. Out of which 56 were of right side and 44 were of left side. Damaged and deformed scapulae were excluded from the study.

Shapes of glenoid fossa were classified into three groups as previously described by Schmpf M et al., on the basis of presence or absence of notch on the anterior margin of fossa [6]. These are: Oval shape- absence of notch, Pear shape- presence of indistinct notch and Inverted comma shape- presence of distinct notch. Slightly raised margin around the glenoid fossa was used to define the border of fossa.

All morphometric parameters were measured by using digital Vernier caliper in millimeter with accuracy of 0.01mm. Different measured parameters of glenoid fossa were measured as by Akhtar MJ et al., [Table/Fig-1] [7].

Superio-Inferior diameter of glenoid fossa (SI)-was measured as maximum distance from most prominent point of supra-glenoid tubercle to inferior point on glenoid margin [7].



[Table/Fig-1]: Measurements of glenoid cavity; AB= Superior-inferior diameter; CD= Antero-posterior diameter-2

Anterio-Posterior diameter-1 of glenoid fossa (AP-1)-was measured as maximum breadth of margin of glenoid cavity, perpendicular to glenoid cavity height [7].

Anterio-Posterior diameter-2 of glenoid fossa (AP-2) – was measured as maximum breadth of upper half of glenoid cavity [7].

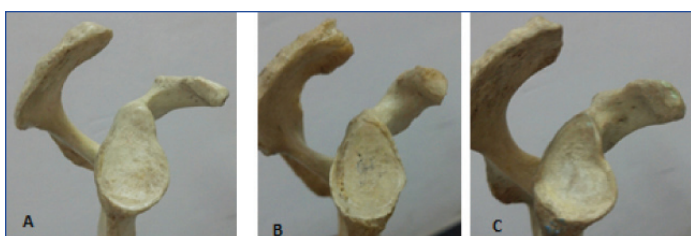Glenoid Cavity Index (GCI)-calculated by (Anterio-posterior diameter-1 ÷ Superio-inferior diameter) × 100 [7].

STATISTICAL ANALYSIS

To reduce the inter-observer error each measurement were taken by one researcher at three different times. All the data were tabulated and analysed by using SPSS version 22.0. Mean, minimum and maximum values of all parameters were derived with Standard deviation. The values of right and left side were analysed and compare by using unpaired t-test. The p-value ≤0.05 was taken as statistically significant.

RESULTS

In present study, total 100 scapular glenoid cavities were studied, out of which 56 were of right side and 44 were of left side. On the basis of presence or absence of the glenoid notch, three shapes were observed. Most common shape of glenoid cavity in present study was pear shape that is 44% (42.9% on right side and 45.5% on left side) followed by oval shape in 34% (35.7% on right side and 31.8% on left side) and Inverted comma shape in 22% (21.4% on right and 22.7% on left side) [Table/Fig-2,3]. Mean values of measured parameters were, SI diameter 34.24±3.27 mm, AP-1 diameter 23.93±2.67 mm, AP-2 diameter 12.96±1.84 mm and glenoid cavity index 70.12±7.13 in total scapulae [Table/Fig-4].



[Table/Fig-2]: Different shapes of glenoid cavity A-Pear, B=Oval and c= Inverted Comma.

Shape	Right Side N (%)	Left Side N (%)	Total N (%)
Pear	24 (42.9%)	20 (45.5%)	44 (44%)
Oval	20 (35.7%)	14 (31.8%)	34 (34%)
Inverted Comma	12 (21.4%)	10 (22.7%)	22 (22%)

[Table/Fig-3]: Different shapes of glenoid cavity.

Morphometric measurements of right, left side and total are shown in [Table/Fig-4,5]. The difference between the values of right and

	Mean (mm)±SD	Minimum (mm)	Maximum(mm)
SI	34.24±3.27	27.75	43.25
AP-1	23.93±2.67	18.55	28.43
AP-2	12.96±1.84	9.13	17.01
GCI	70.12±7.13	50.95	86.36

[Table/Fig-4]: Morphometric values of total glenoid cavity irrespective of side (N=100).

left side were statistically non-significant (p>0.05), except for AP glenoid diameter-2 (p<0.05).

DISCUSSION

In the present study the common shape of glenoid cavity observed was Pear shape followed by oval and inverted comma shape on both the side. Many other authors reported Pear shaped glenoid cavity as a common shape. Rajput HB et al., Akhtar MJ et al., Mamatha T et al., and D Santoshkumar A et al., observed Pear shaped glenoid cavity as a common shape followed by inverted comma and oval shape in Indian scapulae [5,7-9], while Prescher A et al., [2] in German scapulae, Sinha P et al., and present study in Indian scapulae reported pear shape as common shape followed oval shape [2,10]. In Egyptian scapulae Nasr El Din WA et al., [11] and in Turkish scapulae Coskun N et al., reported oval shape of glenoid cavity as a common shape followed by pear shape while Gamal Hamed ESM et al., reported pear shape as a common followed by inverted comma and oval shape in Egyptian scapulae [Table/Fig-6,7] [11-13].

The mean SI diameter of glenoid cavity of scapula in present study was 34.84±3.46 mm in total scapula, 34.84mm±3.46 on right side and on left side it was 33.48±2.88 mm. The values of SI diameter measured by Rajput HB et al., Mamatha T et al., and Sinha P et al., were almost similar with the present study [5,8,10], while Akhtar MJ et al., D Santoshkumar A et al., and Mahto AK et al., and reported higher values 36.03 mm, 37.03 mm, & 36.2 mm respectively in comparison to present study in which it was 34.84 mm [7,9,14]. Values of SI glenoid diameter of left side were reported higher then right side in the study of Mamatha T et al., and Sinha P et al., [8,10]. Churchill RS et al., in United states of America, Nasr El-Din WA et al., in Egyptian scapulae Coskun N et al., in Turkish scapulae, and Aigboug EO et al., in Nigerian scapula reported higher values of SI diameter in comparison to present study [3,11,12,15], while Gamal Hameed ESM et al., in Egyptian scapulae reported smaller values of SI diameter than the present study [Table/Fig-8,9] [13].

In present study, the measured mean values of anterio-posterior-1 diameter of glenoid cavity were as 23.93±2.67 mm in total, 24.25±2.55 mm on the right and 25.52±2.78 mm on the left side. Values of AP-1 glenoid diameter of left side were slightly higher than right side in present study but this difference is not statistically significant. Almost Similar values of AP-1 diameter of right side were reported by other Indian studies like Rajput HB et al., and Akhtar MJ et al., Mamatha T et al., Sinha P et al., Mahto AK et al., [5,7,8,10,14], while D Santoshkumar A et al., reported higher values [9]. In Turkish scapulae the values of AP-1 diameter were almost similar with the present study [12], while Churchill RS et al., in United states of America, WA Naser El Din et al., in Egypt and Aigbogun EO et al., in Nigeria had reported higher values than present study [3,11,15] and the values reported by Gamal Hameed ESM et al., in Egyptian scapulae were smaller than present study [13]. The values of left side AP-1 glenoid diameter of present study were higher in comparison to other studies [Table/Fig-8,9].

Anterio-posterior-2 diameter reported by present study as mean on right side was 13.69±1.54 mm, on left side 12.01±1.77 mm and in total 12.96±1.84 mm. Values of right AP-2 glenoid diameter were slightly higher than left side and this difference was found statistically significant (p≤0.05). The values of AP-2 diameter

	Right Side			Left Side			t-value	p-value
	Mean±SD	Minimum	Maximum	Mean±SD	Minimum	Maximum		
SI	34.84±3.46	29.45	43.25	33.48±2.88	27.75	39.10	1.950	0.058
AP-1	24.25±2.55	19.79	28.43	25.52±2.78	18.55	28.33	1.509	0.139
AP-2	13.69±1.54	10.08	17.01	12.01±1.77	9.13	15.26	4.243	0.001*
GCI	69.87±1.54	58.33	86.36	70.44±7.59	50.95	85.51	-.021	0.983

[Table/Fig-5]: Morphometric measurements of Glenoid cavity of right and left side, t-value and p-value.

	Number Right & Left	Pear		Oval		Inverted Coma	
		Right (%)	Left (%)	Right (%)	Left (%)	Right (%)	Left (%)
Rajput HB et al., [5]	R=43 L=57	49	46	16	15	35	39
Mamatha T et al., [8]	R=98 L=104	46	43	20	24	34	33
Akhtar MJ et al., [7]	R=126 L=102	51.59	49.02	13.49	13.73	34.92	37.25
Sinha P et al., [10]	R=21 L=32	23	42	8	13	9	6
D.Santoshkumar Ankushrao et al., [9]	R=53 L=54	57	50	13	15	30	35
Present study	R=56 L=44	42.9	45.5	35.7	31.8	21.4	22.7

[Table/Fig-6]: Shapes of glenoid cavity observed by different Indian authors.

	Coskun N et al., [12] Turkish	Prescher A et al., [2] Germany	Gamal Hameed ESM et al., [13] Egypt	Nasr El-Din WA et al., [11] Egypt	Present Study
N	R=44 L=46	Male=118 Female=118	Right-38 Left-30	R=160 L=80	R=56 L=44
Pear	28%	55%	45.59%	R-35% L-27.50%	R-42.9 L-45.5
Oval	72%	45%	25.53%	R-48.75% L-52.50%	R-35.7 L-31.8
Inverted Comma	-	-	30.88%	R-16.25% L-20%	R-21.4 L-22.7

[Table/Fig-7]: Shapes of glenoid cavity observed by different authors of other countries.

	Number Right & Left	SI (mean±SD) mm		AP-1 (mean±SD) mm		AP-2 (mean±SD) mm		GCI (mean±SD) %	
		Right	Left	Right	Left	Right	Left	Right	Left
Rajput HB et al., [5]	R=43 L=57	34.76±3.0	34.43±3.21	23.31±3	22.92±2.80	15.10±2.54	13.83±2.45	-	-
Mahto AK et al., [14]	R=40 L=40	36.2 ±.17	33.2±1.8	24.2±1.3	22.5±1.4	-	-	-	-
Mamatha T et al., [8]	R=98 L=104	33.67±2.82	33.92±2.87	23.35±2.04	23.05±2.30	16.27±2.01	15.77±1.96	-	-
Akhtar MJ et al., [7]	R=126 L=102	36.03±3.15	35.52±3.12	23.67±2.53	23.59±2.47	16.30±2.16	16±2.34	66.13±8.67	66.73±7.47
Sinha P et al., [10]	R=21 L=32	33.64±3.01	34.44±3.27	23.22±2.85	23.31±3.12	18.07±2.64	18.01±2.56	-	-
D Santosh kumar A et al., [9]	R=53 L=54	37.03±3.55	36.52±4.12	24.61±3.53	24.56±4.47	16.31±3.16	16.2±3.64	65.13±7.67%	65.73±8.47%
Present Study	R=56 L=44	34.84±3.46	33.48±2.88	24.25±2.55	25.52±2.78	13.69±1.54	12.01±1.77	69.87±1.54	70.44±7.59

[Table/Fig-8]: Morphometric values of glenoid fossa reported by different Indian authors.

	Coskun N et al., [12] Turkish	Churchil RS et al., [3] United states of America	Gamal Hameed ESM et al., [13] Egypt	W.A.Nasr El-Din et al., [11] Egypt	Aigbogun E O et al., [15] Nigeria	Present Study India
N	R=44 L=46	Male-100 Female-72	Right-38 Left-30	Right-160 Left-80	Right=96 Left=104	Right=56 Left=44
SI diameter	36.3mm±3	Male-37.5±2.2 Female-32.6±1.8	Right-33.1±3.9 Left-28.7±4.1	Right-38.88±2.63 Left-39.01±2.49	Right-37.71±4.24 Left-36.22±3.58	Right-34.84±3.46 Left-33.48±2.88
AP-1 diameter	24.6mm±2.5	Male-27.8±1.6 Female-23.6±1.5	Right-23.35±2.04 Left-23.02±2.3	Right-28.31±2.38 Left-27.99±2.55	Right-26.20±3.30 Left-24.35±3.64	Right-24.25±2.55 Left-25.52±2.78
AP-2 diameter	-	-	-	Right-21.33±2.49 Left-21.69±2.06	-	Right-13.69±1.54 left-12.01±1.77

GI	-	-	-	-	Right-69.59±5.53 Left- 67.11±6.03	Right-69.87±1.54 Left- 70.44±7.59
----	---	---	---	---	-----------------------------------------	-----------------------------------------

[Table/Fig-9]: Morphometric values of glenoid fossa measured by different authors Of other countries.

reported by present study were much less than the values reported by other Indian studies as well as by studies of other countries. This difference could be racial [Table/Fig-7].

The mean values of Glenoid cavity index of present study were; on right side 69.87±1.54, on left side 70.44±7.59 and in total glenoid fossa 70.12±7.13. Values of GCI of present study were found to be higher than the other values reported by other Indian authors (Akhtar MJ et al., and D Santoshkumar A et al., [7,9]. While the values of GCI reported by and Gamal Hamed ESH et al., in Egyptian scapula Aigbogun EO et al., in Nigerian scapulae was higher than the present study [Table/Fig-8,9] [13,15].

The difference in morphometric values of glenoid fossa of present study with other Indian as well as of other countries could be racial.

LIMITATION

Although the sample size of present study was small but the morphological and morphometric values of glenoid fossa of present study may add some data.

CONCLUSION

The measurements and facts drawn in this study will be helpful to the orthopaedician for the better understanding of the anatomy of gleno-humeral joint and they may use these informations for surgical corrections of the diseases of this joint and the facts may be helpful in choosing the right size prosthesis in shoulder arthroplasty.

REFERENCES

- [1] Standardizing S. Gray's anatomy. The anatomical basis of clinical practice. 41th ed. London: Elsevier Churchill Livingstone; 2016;803,813.
- [2] Prescher A, Klumpen T. The glenoid notch and its relation to the shape of the glenoid cavity of the scapula. *J Anat.* 1997;190(Pt 3):457-60.
- [3] Churchill RS, Brems JJ, Kotschi H. Glenoid size, inclination, and version: An anatomic study. *J Shoulder Elbow Surg.* 2001;10(4):327-32.
- [4] Hughes RE, Bryant CR, Hall JM, Wening J, Hutson LJ, Kuhn JE et al. Glenoid inclination is associated with full thickness rotator cuff tears. *Clin Orthop Related Res.* 2003;407:86-91.
- [5] Rajput HB, Vyas KK, Shroff BD. A study of morphological patterns of glenoid cavity of scapula. *National J Med Res.* 2012;2(4):504-07.
- [6] Schrupf M, Maak T, Hammoud S, Craig EV. The glenoid in total shoulder arthroplasty. *Curr Rev Musculoskelet Med.* 2011;4(4):191-99.
- [7] Akhtar MJ, Kumar B, Fatima N, Kumar V. Morphometric analysis of glenoid cavity of dry scapulae and its role in shoulder prosthesis. *Int J Res Med Sci.* 2016;4(7):2770-76.
- [8] Mamatha T, Pai SR, Murlimanju BV, Kalthur SG, Pai MM, Kumar B. Morphometry of glenoid cavity. *Online J Health Allied Sci.* 2011;10(3):01-04.
- [9] Ankushrao SD, Dombhe DD. Morphological and Morphometrical study of scapulae in Western Indian Population. *Ind J Clin Anat Physiol.* 2017;4(3):298-303.
- [10] Sinha P, Bhutia KL, Tamang B, Sarda RK. Morphometric study of glenoid cavity of dry human scapula. *Int J Med Res Prof.* 2016;2(3):86-90.
- [11] Wael Amin Nasr EL-DIN, Mona Hassan MA. A morphometric study of the patterns and variations of the acromion and glenoid cavity of the scapulae in Egyptian Population. *J Clin Diagn Res.* 2015;9(8):8-11.
- [12] Coskun N, Karaali K, Cevikol C, Demirel BM, Sindel M. Anatomical basics and variations of the scapula in Turkish adults. *Saudi Med J.* 2006;27(9):1320-25.
- [13] Gamal Hamed ESH. Morphometry of Glenoid fossa in Adult Egyptian Scapulae. *Int J Anat Res.* 2015;3(2):1138-42.
- [14] Mahto AK, Omar S. Dimensions of glenoid fossa of scapula: implications in the Biomechanics of an implant design. *Int J Sci Stud.* 2015;3(4):146-48.
- [15] Aigbogun EO, Oladipo GS, Oyakhire MO, Ibeachu PC. Morphometry of the glenoid cavity and its correlation with selected geometric measurements of the scapula. *Bangladesh J Med Sci.* 2017;16(4):572-79.

PARTICULARS OF CONTRIBUTORS:

1. Assistant Professor, Department of Anatomy, Rohilkhand Medical Collage and Hospital, Bareilly, Uttar Pradesh, India.
2. Professor and Head, Department of Community Medicine, Rohilkhand Medical Collage and Hospital, Bareilly, Uttar Pradesh, India.
3. Assistant Professor, Department of Anatomy, Varun Arjun Medical Collage and Rohilkhand Hospital, Banthra, Shahjahanpur, Uttar Pradesh, India.
4. Professor and Head, Department of Anatomy, Rohilkhand Medical Collage and Hospital, Bareilly, Uttar Pradesh, India.

NAME, ADDRESS, E-MAIL ID OF THE CORRESPONDING AUTHOR:

Dr. Arun Singh,
Rohilkhand Medical College Campus, Bareilly, Uttar Pradesh, India.
E-mail: arunspm@gmail.com

Date of Submission: **Mar 06, 2019**

Date of Peer Review: **Mar 11, 2019**

Date of Acceptance: **Apr 01, 2019**

Date of Publishing: **Jul 01, 2019**

FINANCIAL OR OTHER COMPETING INTERESTS: None.